

Recurrent Pyogenic Granulomas with Underlying Arteriovenous Malformation: An Exclusively Rare Entity

Banashree Majumdar, Atul Jain, Sanchaita Bala, Anindya Bandyopadhyay¹, Archana Singh¹, Arghyaprasun Ghosh

Abstract

We report a case of recurrent localized pyogenic granulomas with underlying arteriovenous malformation in an 11-year-old male child on upper back with onset in early infancy.

Key Words: Arterio-venous malformation, lobular capillary hemangioma, pyogenic granuloma

From the Departments of Dermatology Venerology and Leprosy and ¹Radiology, Institute of Post Graduate Medical Education and Research and Seth Sukhlal Karnani Memorial Hospital, Kolkata, West Bengal, India

Address for correspondence: Dr. Banashree Majumdar, Room No 339, PG Junior Doctor Hostel, Institute of Post Graduate Medical Education and Research and Seth Sukhlal Karnani Memorial Hospital, 242 A. J. C Bose Road, Kolkata - 700 020, West Bengal, India. E-mail: banashreemajumdar1@gmail.com

What was known?

Pyogenic granuloma is a common tumor with possible recurrences at the same site or different sites.

Introduction

Pyogenic granuloma (PG) or granuloma pyogenicum is a vascular tumor showing rapid growth and consist of lobular proliferation of capillaries in a loose stroma.^[1] It usually occurs at the site of a recent injury or burn. Rarely, PG may be seen within a port wine stain.^[2] The term PG was introduced by Hartzell in 1904.^[3] We are reporting a rare association of recurrent localized PGs with underlying arteriovenous malformation (AVM) arising in infancy.

Case Report

An 11-year-old Hindu male child presented to our OPD with complaints of nodules arising over a plaque on upper back since age of 6 months. There was a history of bleeding from the lesions with minimal trauma. The parents first noticed an erythematous patch over the upper back of the child at the age of 3 months. The nodules started appearing at 6 months age which

gradually increased in size and number. The child underwent repeated surgical intervention from other centers over the years for the same resulting in multiple scars in the affected area. On examination a solitary nodule, which used to bleed on slightest trauma, was seen over an area of atrophic looking dyspigmented 8 × 10 cm plaque, situated in the interscapular region. On close examination a couple of small papules were also seen over the area which parents said were the initiating lesions [Figure 1]. The atrophic plaque was warm on palpation with an irregular feel without any thrill or bruit. The child was otherwise normal. A probable diagnosis of PG was made with an underlying vascular malformation. Routine investigations were within normal limit. A color Doppler study of the affected area showed multiple vascular malformations with both an arterial spectral and arterialized pattern in vein [Figure 2]. These findings were suggestive of multiple AVMs. Histopathological examination (HPE) of the nodular lesion revealed capillary proliferation in lobules over the upper and mid-dermis with an overlying thinned epidermis showing elongation of rete ridges at the edges. The dermis immediately below shows scattered lymphatic channels and a localized area of vascular spaces [Figure 3]. The capillary spaces of varying sizes seen in the upper dermis are not interconnected [Figure 4]. Considering all the

Access this article online

Quick Response Code:



Website: www.e-ijd.org

DOI: 10.4103/0019-5154.160538

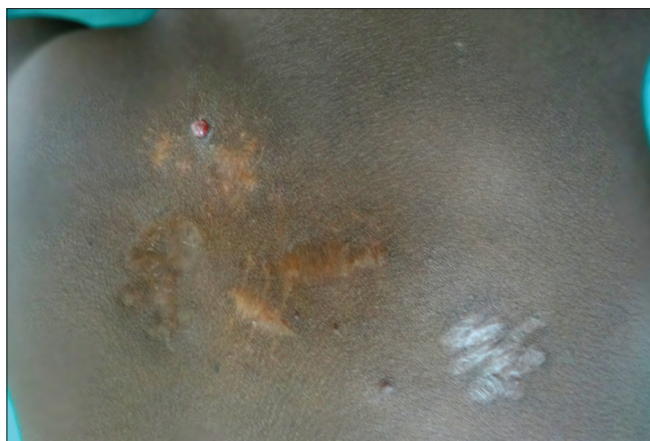

Figure 1: Multiple pyogenic granulomas over a circumscribed scarred area on back

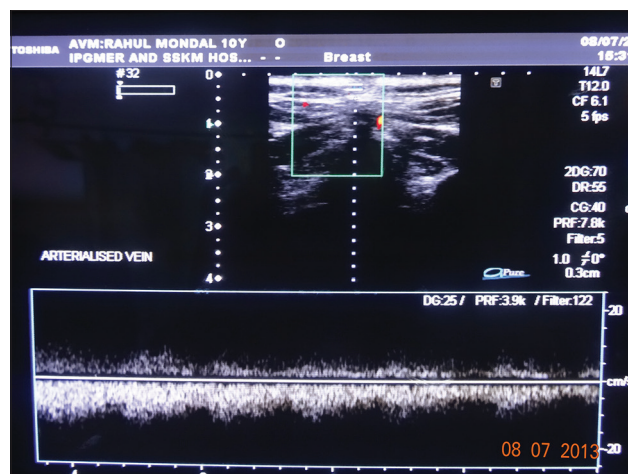


Figure 2: Doppler study showing features of AVM

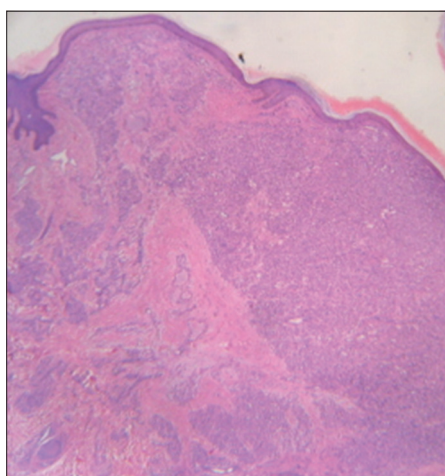


Figure 3: Photomicrograph showing lobular capillary proliferation in upper dermis with hypertrophy of rete ridges at edges. (H and E X100)

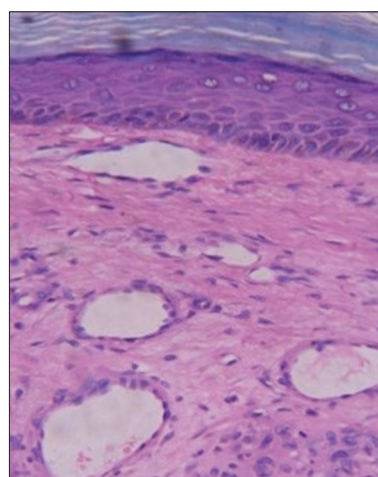


Figure 4: Photomicrograph showing dilated capillary spaces. (H and E X400)

above features we reached at a diagnosis of recurrent PGs with an underlying AVM.

Discussion

In 1844, Hullihen reported the first case of PG in the English literature.^[3] Histopathologically, two types of PG namely lobular capillary hemangioma (LCH) type and non-LCH type have been described. It is considered to be reactive and not neoplastic in nature.^[3] Once the PG becomes chronic it loses its lobular pattern.^[4]

PG is a common condition affecting both sexes with a predilection for male. It usually occurs in the second decade of life but may affect any age group including children and young adults. In a small number of cases, patient gives a history of an injury, usually of penetrating kind, a few weeks before the nodule appears. In other cases, no history of injury could be elucidated, but this is likely on the basis of the patient's occupation or the body site affected.^[1] The peculiarity in our case was that the child had an onset in the first year of life without any apparent trauma and the lesions kept on recurring at regular interval

over the circumscribed area described above but not necessarily at the same site.

It is a vascular tumor which is partially compressible without any pulsation and is bright red to brownish red or blue-black in color. It may bleed very easily. The sites of predilection are the hands, especially the fingers, the feet, lips, head and upper trunk, and the mucosal surfaces of the mouth and perianal area. Growth ceases after a few weeks of an initial phase of rapid evolution but spontaneous disappearance is rare. In most of the cases, it is asymptomatic except for bleeding.^[1] In our case, there were brown to black nodules in a circumscribed area on upper back which did not show any pulsation on palpation and used to bleed after trivial trauma.

Histopathologically, lobular proliferations of small blood vessels protrude through a breach in the epidermis to produce a polypoid angiomatous tumor. Rare finding of focal degenerative atypia raise the possibility of malignancy.^[1] Sometimes in children, and rarely in post-treatment cases, satellite lesions having similar

pathology may develop in the vicinity of the primary lesion.^[5] In our case also, there were similar smaller lesions near the lesion of index PG. HPE showed characteristic features of PG and there were no features of malignancy under the microscope.

There are reported cases of multiple PGs developing after exfoliative dermatitis^[6] and, in periungual location, after HAART.^[1] In our case, PG was associated with an underlying AVM which was confirmed by color Doppler study.

The lesions of PG easily respond to simple destructive measures like curettage with cauterization or diathermy coagulation of the base. But, due to the presence of proliferating vessels in the base which extend in a conical manner into the deeper dermis, a considerable proportion of PGs recur after such treatment. Therefore, it is recommended to excise a narrow, but deep, ellipse of skin beneath the lesion with sutural closing of the wound.^[1]

Ideal modality of this case should be the treatment of the underlying cause therefore arterial embolization and/or with surgical resection of the underlying AVM.^[7]

We employed diathermy for destruction of the multiple lesions. Association of underlying AVM with PG has hitherto not been reported in the literature. In our case repeated surgical traumas and probable angiogenic factors from an underlying high flow AVM might be the reason for PGs recurring over a circumscribed area.

What is new?

Recurrent multiple pyogenic granulomas occurring over a circumscribed area with underlying AV malformation has not been reported.

References

1. Judge MR, Mclean WH, Munro CS. Disorder of keratinization. In: Burns T, Breathnach S, Cox N, Griffiths C, editors. *Rook's Textbook of Dermatology*. 8th ed. Singapore: Wiley-Blackwell; 2010. p. 19.1-122.
2. Sheehan DJ, Leshner JL Jr. Pyogenic granuloma arising within a port-wine stain. *Cutis* 2004;73:175-80.
3. Sangamesh NC, Poornima B, Vidya KC, Sakri SB. Extralingival pyogenic granuloma: A rare case report. *J Sci Soc* 2013;40:49-51.
4. Wassef M, Hunt SJ, Santa Cruz DJ, Burnhill RL. Vascular tumors and vascular malformations. In: Burnhill RL, editor. *Dermatopathology*. 3rd ed. New York: McGraw-Hill; 2010. p. 802-56.
5. Sethuraman G, Khaitan BK, Chandra SS, Prasad HR, Agarwal S, Singh MK, *et al.* Pyogenic granuloma with multiple and satellite lesions. *Indian J Dermatol* 2006;51:134-6.
6. Torres JE, Sánchez JL. Disseminated pyogenic granuloma developing after an exfoliative dermatitis. *J Am Acad Dermatol* 1995;32:280-2.
7. Boon LM, Vikkula M. Vascular malformations. In: Goldsmith LA, Katz SI, Gilchrist BA, Paller AS, Leffell DJ, Wolff K, editors. *Fitzpatrick's Dermatology in General Medicine*. 8th ed. New York: McGraw-Hill; 2012. p. 2076-9.

How to cite this article: Majumdar B, Jain A, Bala S, Bandyopadhyay A, Singh A, Ghosh A. Recurrent pyogenic granulomas with underlying arteriovenous malformation: An exclusively rare entity. *Indian J Dermatol* 2015;60:423.

Received: November, 2013. **Accepted:** March, 2014.

Source of support: Nil, **Conflict of Interest:** Nil.